

Intra Tunnel Phaco Fracture : Video Tutorial

Dr Sudhir Singh, MS
JW Global Hospital Research Centre
Mount Abu India 307501
drsudhirsingh@gmail.com

Intratunnel Phacofracture Technique

- Intratunnel phacofracture technique is the new technique of the manual small incision cataract surgery (MSICS).
- In this technique nucleus is broken inside the 4 to 6 mm wide sclero-corneal tunnel with the help of the Lewis lens loop.
- MSICS is significantly faster, less expensive, and less technology-dependent than phacoemulsification and has been extensively practiced in developing countries such as India.
- However, the drawback of most commonly practiced MSICS techniques Blumenthal, visco-expression, irrigating wire vectis, and fish-hook needle is that they all require a large incision of 7 to 9 mm, which leads to induced astigmatism.
- This technique was innovated by Dr Sudhir Singh^{1,2}.

Intra Tunnel Phaco Fracture

Incision Site Planning

Fornix Based Conjunctival Flap

Cautary

Corneo Scleral
Tunnel Construction

Capsular Staining

Capsulorhexis

Hydro-dissection

Nucleus Prolapse In The Anterior
Chamber

Tunnel Enlargement

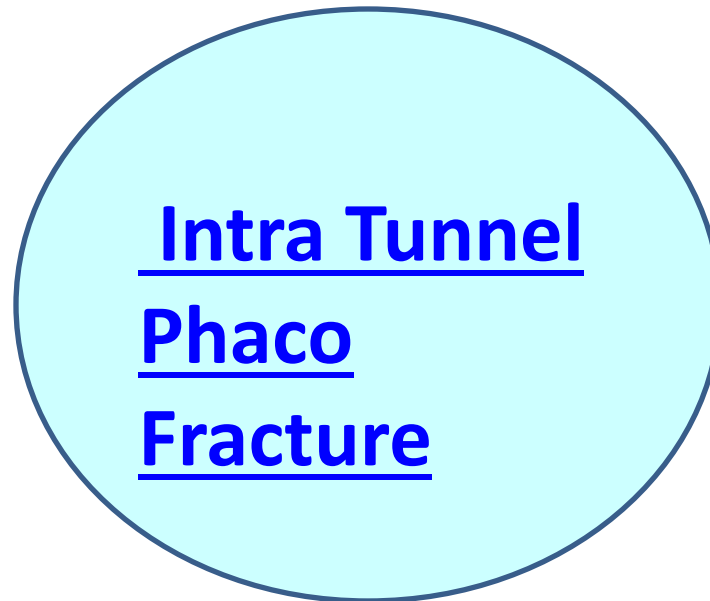
Nucleus Management by
Intratunnel Phacofracture
Technique

Cortical Clean Up By
Irrigation And Aspiration

IOL Implantation

Anterior Chamber Wash

Conjunctival Flap
Reposition



Intra Tunnel Phaco Fracture Videos

- [Intra Tunnel Phaco Fracture A New MSICS Technique with Commentary](#)
- [Manual Small Incision Cataract Surgery \(MSICS\) in White Cataract With Commentary](#)

Intra Tunnel Phaco Fracture

- 4 mm Intra Tunnel Phaco Fracture
- 5.0 mm Intra Tunnel Phaco Fracture
- 5 mm Intratunnel Phacofracture MSICS With Foldable IOL
- 5 mm SICS With Multi focal IOL
- 5.5 mm Intra Tunnel Phaco Fracture
- 6.0 mm Intra Tunnel Phaco Fracture

Visual Outcome Videos

- [Intra Tunnel Phaco Fracture SICS : First Post Operative Day Visual Outcome 14 Cases](#)
- [Multifocal Vision By Mono focal IOL with Intratunnel Phacofracture](#)
- [Multifocal Vision 6/6 N/6 By Monofocal IOL : A Video Case Report](#)

Manual Cataract Refractive Surgery

- [Manual Cataract Refractive Surgery Video](#)
- [Incision Planning Video](#)
- [Multifocal Vision 6/6 N/6 By Monofocal IOL : A Video Case Report](#)

Management Of Difficult Cataract Cases

- [Management Difficult Cataract Case 1 : Hard Nuclear Cataract With Non Dilating Pupil](#)
- [Management Difficult Cataract Case 2 : Posterior Polar Cataract With Ant Vitrectomy](#)
- [Management Difficult Cataract Case 3 : Psuedoexfoliation With Non Dilating Pupil](#)
- [Management Difficult Cataract Case :4 Subluxated Cataract Lens](#)
- [Management Difficult Cataract Case: 5 Lens Induced Glaucoma](#)
- [Management Difficult Cataract Case :6 Subluxated Cataractus Lens](#)
- [Management Difficult Cataract Case 7 : Hard Nuclear Cataract With Non Dilating Pupil And Floppy Iris](#)
- [Management Difficult Cataract Case 8: Traumatic Cataract Retained Intra Lenticular Foreign Body](#)

Intra Tunnel Phaco Fracture Videos

- [Intra Tunnel Phaco Fracture SICS in Rock Hard Black Nuclear Cataract](#)
- [SICS In Black Rock Hard Cataract With Corneal Opacity With Non Dilating Pupil](#)
- [Manual Small Incision Cataract Surgery In Brown Hard Cataract](#)
- [Manual Small Incision Cataract Surgery \(SICS\) With IOL And Trabeculectomy](#)
- [Posterior Polar Cataract ,Small Incision Cataract Surgery \(SICS\)](#)
- [Small incision Cataract Surgery In Hyper Mature Hard Cataract](#)
- [Managing Hard Nuclear Cataract With Pseudo-exfoliation](#)
- [Manual Small Incision Cataract Surgery also known as Manual Phaco](#)

Manual Small Incision Cataract Surgery Pages

- [Surgical Induced astigmatism \(SIA\) Multifocal Vision By Mono Focal IOL](#)
- [Intra Tunnel Phaco Fracture Nucleus Management Technique Videos](#)
- [Manual Small Incision Cataract Surgery \(MSICS\) Page 2](#)
- [Manual Small Incision Cataract Surgery \(MSICS\) Page](#)
- [Ophthalmology Surgery Videos](#)
- [Intratunnel Phacofracture : A Noble MSICS Technique](#)
- [4 mm Intratunnel Phacofracture Manual Small Incision Cataract Surgery](#)
- [Step By Step SICS With Video](#)
- [How To Plan Incisions In MSICS](#)
- [How To Manage Intraoperative Floppy Iris Syndrome](#)
- [Glaucoma And Cataract Combined Surgery](#)
-

References

1. Singh S. First postoperative day visual outcome following 6 mm manual small incision cataract surgery using intratunnel phacofracture technique. [US Ophthalmic Review. 2014;7\(1\):26-30.](#)
2. Singh Sudhir. Step-by-step: Intratunnel Phacofracture. [Cataract & Refractive Surgery Today Europe | MAY 2016:48-51](#)

Contact Us

- [LinkedIn](#)
- [Twitter](#)
- [Like us on Facebook](#)
- **Skype Id** drsudhirsingh
- **Google+**
- resp2020@gmail.com
- drsudhirsingh@gmail.com